CHAPTER 11

Diagnostic tools for gallstone

Sarita Kumari[1], Kusumika Krori Dutta[2], Harsha Karamchandani[3] and Jalall S. Kehkeshan[4]
[1]Department of Electronics & Communication Engineering, Amity University Jharkhand, Ranchi, Jharkhand, India
[2]Electrical and Electronics Engineering, M S Ramaiah Institute of Technology, Bangalore, Karnataka, India
[3]Department of Electronics & Communication, Nitte Meenakshi Institute of Technology, Bangalore, Karnataka, India
[4]Electronics & Communication Engineering, Presidency University, Bangalore, Karnataka, India

Introduction

Gallstone-related issues arise in asymptomatic individuals at a rate of 1%–4% each year. Because the balance of risks and benefits favors "watch and wait," prophylactic cholecystectomy is not necessary for most of the population (Sanders & Kingsnorth, 2007). As shown in Fig. 11.1, the gallbladder is a little, pear-shaped organ that is located beneath your liver on the right side of your belly. Bile, a digestive fluid stored in the gallbladder, is discharged into your small intestine. Bile is the fluid that liver produces which helps digest fats in the food you eat. The digestive system includes the gallbladder which stores bile. The three primary components of bile are cholesterol, bilirubin, and bile salts. Your digestive system breaks down lipids with the aid of bile. The biliary tract, a network of bile ducts, connects your gallbladder to other areas of your digestive system. The biliary tract is a pipe-like structure that transports bile from your liver to your small intestine. It is also referred to as the biliary system or biliary tree. Bile is stored in your gallbladder before you begin to consume. Your gallbladder receives signals when you begin eating, causing it to constrict and force the stored bile through the biliary canal. The common bile duct, your major bile duct, is where the bile ultimately ends up. In the duodenum, the first section of your small intestine, where food is ready to be digested, bile travels through the common bile duct. Your gallbladder is empty after eating and looks like a deflated balloon that must be filled again.

When there is an imbalance in the chemical components of bile, one or more of the components precipitate out, resulting in gallstones. Although some risk factors are known, the exact cause of this is unclear. Several issues can affect the gallbladder, which is a sac near the liver that stores bile. Gallstones are hardened deposits of the digestive fluid bile, that

Gallstone Formation, Diagnosis, Treatment, and Prevention
DOI: https://doi.org/10.1016/B978-0-443-16098-1.00013-8
© 2024 Elsevier Inc. All rights are reserved, including those for text and data mining, AI training, and similar technologies.

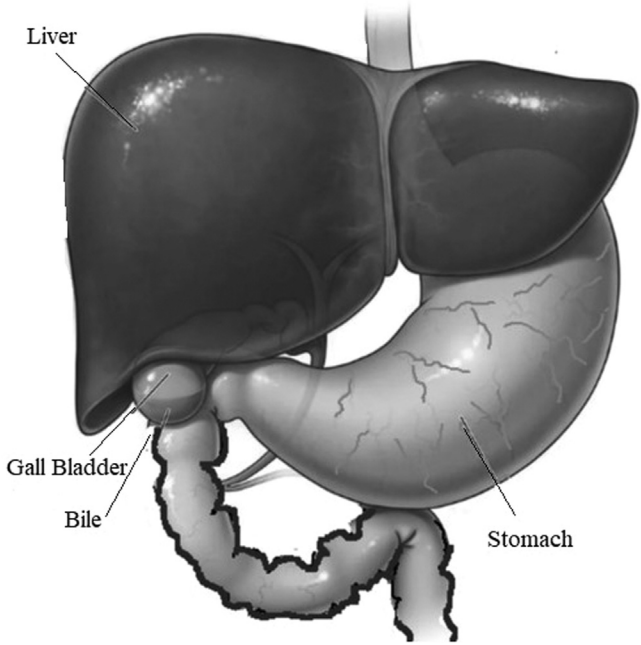

Figure 11.1 Image of gallbladder. *https://my.clevelandclinic.org/health/body/21690-gallbladder*.

can form within the gallbladder. They vary in size and shape from as small as a grain of sand to as large as a golf ball. The balance may favor treatment because a young patient is more likely to experience issues because they have more time to do so. Furthermore, smaller stones may pose a greater risk than larger ones.

Most gallstones are not visible on standard X-rays, but an ultrasound makes them simple to spot. Symptomless gallstones are common. Even if gallstones are detected on an ultrasound or CT scan and you experience symptoms that may or may not be related to them, it may be challenging for your doctor to determine whether the stones are the cause of your symptoms.

Reasons to develop gallstone

1. Too much cholesterol in your bile
2. Too much bilirubin in your bile
3. Your gallbladder doesn't empty correctly.

Common symptoms of gallstone

1. Your upper right abdomen is experiencing a sudden, sharp pain that is getting worse very quickly
2. Discomfort following meals, especially those high in fat, or at night
3. You feel a sharp ache in the middle of your belly, just below your breastbone, that is escalating quickly
4. Backache between your shoulder blades
5. Your right shoulder hurts
6. Sickness or vomiting

Gallbladder conditions

The gallstone can be deadly if not treated in time. Various conditions may develop due to ignorance of the diagnosis/treatment of gallstone such as:

Gallstones (cholelithiasis)

Bile components may solidify in the gallbladder for unknown causes, resulting in gallstones. Gallstones are common and mostly painless, but they may cause discomfort, nausea, or inflammation.

Cholecystitis

Gallbladder infection is frequently brought on by a gallstone inside the gallbladder. When the infection persists or recurs, cholecystitis can lead to surgery and cause excruciating pain and fever.

Gallbladder cancer

Although rare, cancer can affect the gallbladder. It is difficult to diagnose and is usually found at late stages when symptoms appear. Symptoms may resemble those of gallstones.

Gallstone pancreatitis

An impacted gallstone blocks the ducts that drain the pancreas. Inflammation of the pancreas results, in a serious condition.

Risk factors of having gallstones

Factors that may increase your risk of gallstones include: (1) being a female, (2) being age 40 or older, (3) being overweight or obese, (4)

pregnancy, (5) consuming high-fat diet, (6) consuming high-cholesterol diet, (7) consuming a low-fiber diet, (8) having a family history of gallstones, (9) having diabetic condition, (10) having liver disease, (11) taking certain medication.

How are gallstones diagnosed and evaluated?

Blood test

Blood tests can show signs of infection or inflammation of the bile ducts, gallbladder, pancreas, or liver caused by gallstones. Although these tests are not done specifically for gallstone disease, a simple blood test, i.e., liver function tests (LFTs), may be recommended to find out the enzyme levels in the liver that can show inflammation in the gallbladder caused by gallstones.

Plain films

Gallbladder disease is diagnosed using a variety of diagnostic procedures. Gallstones that have calcified can be seen on an easy abdomen X-ray. This imaging technique is only marginally beneficial because only 10% of gallstones are hardened. Plain X-rays can also reveal porcelain gallbladders. This unusual disorder is brought on by calcification of the gallbladder wall. The oral cholecystogram (OCG) was created in 1924 by two American surgeons. The OCG is carried out via oral administration of iopanoic acid. This substance, which has an iodine base, enters the intestines and gathers in the gallbladder.

It turns into an extremely radio-opaque liquid within the gallbladder when it interacts with bile salts. This will show the location of any gallstones the gallbladder may have. In 1954, the intervenous cholangiogram was created. It was mostly used to assess the bile ducts and search for obstructions or stones there. An intravenous injection of iodine-based dye is given. Then it is concentrated in the liver before being eliminated by the bile ducts. Because the gallbladder might occasionally be completely bypassed as the dye traveled straight from the bile ducts into the small intestine, the intervenous cholangiogram was a poor test for assessing the gallbladder itself. Nowadays, intravenous and OCGs are seldom ever utilized (Jones et al., 2021).

Ultrasound scan

Ultrasound is the best imaging test for finding gallstones. Ultrasound uses a device called a transducer, which bounces safe, painless sound waves off

your organs to create an image or picture of their structure. Gallstones can usually be confirmed using an ultrasound scan, which uses high-frequency sound waves to create an image of the inside of the body. The abdominal ultrasound is the most accurate diagnostic procedure for identifying gallbladder illness. Gallstones can be detected with 90%–95% accuracy with this noninvasive method. In acute cholecystitis, pericholic fluid and swollen gallbladder walls can also be seen. Abdominal ultrasounds can also detect gallbladder sludge and, rarely, bile duct stones. Possible gallbladder neoplasms may be found using ultrasonography of the gallbladder (Negrão De Figueiredo et al., 2019).

The first test to detect gallbladder disease is not endoscopic ultrasound, generally known as endoscopic ultrasonography (EUS). It is inappropriate to utilize it as a technique for diagnosing cholecystitis. It is useful for evaluating and staging pancreatic, gallbladder, and bile duct tumors. Biopsies can also be utilized to diagnose tissue.

Ultrasound is a noninvasive method of imaging soft tissue in real-time. It uses ultrasonic waves measured using MHz, produced because of the inverse piezoelectric (pressure electricity) effect. A characteristic feature of the ultrasound examination is the inability to visualize bone and air-filled structures because of the propagation of the sound waves. Fig. 11.2 shows a picture of ultrasonography machine used for abdominal scans for various applications.

Ultrasound imaging utilizes the interaction of sound waves with living tissue to produce an image of the tissue or, in Doppler-based modes, determine the velocity of a moving tissue, primarily blood (Fig. 11.2). Ultrasound works on the reflection of high-pitched sound waves at the boundary between two materials (individual tissues have different densities). The reflected wave is recorded and analyzed for intensity (amplitude) and recovery time (determining the location of the tissue). This allows you to assess the size, shape, and structure of organs. To gather quantitative structural and functional data from the target organ, these dynamic, real-time images can be examined. Commercially accessible ultrasound systems now have the spatial and temporal resolution to obtain precise images because of advancements in ultrasound imaging technology (Smereczyński et al., 2020). Ultrasound refers to sound waves that are not detectable by the human ear with frequencies greater than 20,000 cycles/s (Hz). Diagnostic ultrasound commonly uses frequencies between 2 and 15 MHz (106 cycles/s). Intravascular transducers commonly use frequencies up to 30 MHz, and ultrasound biomicroscopic systems with

Figure 11.2 Image of ultrasonography machine.
Adapted from open source.

transducers using frequencies up to 100 MHz have been reported (Foster et al., 2000; Turnbull, 1999). At these frequencies, sound waves are transmitted through soft tissue relative to the acoustic impedance of each tissue. The acoustic impedance of a particular tissue is the product of the transmission velocity of sound and the tissue density. The transmission

velocity in most soft tissues and blood is nearly uniform at 1540 m/s (Rumack et al., 1998). Therefore, the acoustic impedance of most soft tissue is primarily a function of the tissue density. When two tissues with different densities are located next to each other, an acoustic impedance mismatch is created, and sound waves are reflected by the mismatch.

A small portable device called a transducer is applied to your skin and dragged over your upper belly during the ultrasound scan used to detect gallstones, which is similar to the ultrasound scan used to detect pregnancy.

The transducer emits sound waves that travel through your skin and into your body. They create an image on a display as they reflect from the body tissues. It normally takes 10–15 minutes to accomplish this painless treatment. There may be some doubt when gallstones are identified as to whether any stones have entered the bile duct.

An ultrasound scan can sometimes reveal gallstones in the bile duct. It may require treatment if they are not visible, but your testing indicates the bile duct may be compromised. The ultrasound enables medical professionals to view the organs, tissues, and blood vessels and determine whether there are any concerns. The nicest part about this treatment is that there is no need for an incision. This method is frequently used because there are no radiations involved. These imaging methods' benefits include no-invasive properties, the use of non-ionizing radiation, simple and real-time imaging, Portable equipment, repeatable and simple to store, fewer artifacts, etc. The drawbacks include dependency on the operator and the tools, hard tissue is not detectable, and deep structures being unable to locate.

MRI scan

Magnetic resonance imaging (MRI) devices create precise images of your organs using magnets and radio waves. Strong magnetic fields and radio waves are used in this kind of scan to provide precise images of the interior of the body. To check for gallstones in the bile ducts, an MRI scan may be performed.

Protons in the body are forced to align with the magnetic field created by the strong magnets used in MRI machines. The protons are activated and spin out of equilibrium when a radiofrequency current is pulsed through the patient, which causes them to struggle against the magnetic field. The energy produced as the protons realign with the magnetic field

can be detected by the MRI sensors when the radiofrequency field is switched off. The surroundings and the chemical makeup of the molecules affect how long it takes for the protons to realign with the magnetic field and how much energy is released. Based on these magnetic characteristics, doctors can distinguish between different types of tissues. A patient is positioned inside a huge magnet to create an MRI image and must maintain extreme stillness throughout the imaging procedure to prevent image blurring. Before or during the MRI, a patient may receive intravenous contrast agents (typically including the element gadolinium) to hasten the rate at which protons realign with the magnetic field. The image becomes brighter as the protons realign more quickly. MRI has an advantage over CT in being able to detect flowing blood and cryptic vascular malformations. It can also detect demyelinating disease and has no beam-hardening artifacts, similar to CT. Thus, the posterior fossa is more easily visualized on MRI than CT. Imaging is also performed without any ionizing radiation.

The results of MRIs may be identical to those of a CT scan. When assessing the biliary ducts, a magnetic resonance cholangiopancreatography, or MRCP, is a noninvasive imaging test that can be used. It can identify bile duct strictures, tumors, and stones down to a few millimeters in size. An invasive procedure, called endoscopic retrograde cholangiopancreatography (ERCP), is also used to identify biliary system tumors, strictures, and stones. Using biopsies, stent placement, and the extraction of retained bile duct stones, this treatment can also be used to treat and make a more certain diagnosis. The danger of iatrogenic consequences like pancreatitis is increased by this, though. Another treatment that provides a clear view of the pancreatic head and bile ducts is EUS (de Savornin Lohman et al., 2019).

The most common MRI imaging sequences are T1-weighted and T2-weighted scans. T1-weighted images are produced by using short TE and TR times. The contrast and brightness of the image are predominately determined by T1 properties of tissue. Conversely, T2-weighted images are produced by using longer TE and TR times. In these images, the contrast and brightness are predominately determined by the T2 properties of tissue. In general, T1- and T2-weighted images can be easily differentiated by looking at the Cerebrospinal Fluid (CSF). CSF is dark on T1-weighted imaging and bright on T2-weighted imaging. A third commonly used imaging sequence is the Fluid Attenuated Inversion Recovery (Flair). The Flair sequence is like a T2-weighted image except that the

TE and TR times are very long. By doing so, abnormalities remain bright but normal CSF fluid is attenuated and made dark. This sequence is very sensitive to pathology and makes the differentiation between CSF and an abnormality much easier.

The limitation of MRI includes the following: It is subject to motion artifacts, and it requires prolonged acquisition time for many images. It is considered inferior imaging as compared to CT in various applications such as detecting acute hemorrhage and in the detection of bony injury.

Cholangiography

More information on the condition of your gallbladder can be obtained through a procedure called cholangiography. The intervenous cholangiogram was developed in 1954. It was primarily used to evaluate the bile ducts and to look for stones within these bile ducts. An iodine-based dye is injected intravenously. It is then concentrated in the liver and excreted into the bile ducts.

Cholangiography entails the use of an X-ray dye. The dye may be injected into your bloodstream or bile ducts during surgery; alternatively, an endoscope may be utilized and placed through your mouth. After the dye injection, X-ray images are captured. They will show you any abnormality in your biliary or pancreatic systems. If your gallbladder and bile systems are working properly, the dye will be absorbed in the appropriate places. At this point, your doctor could try to remove any obstructions discovered during the test using an endoscope. An ERCP is being performed in this case. ERCP is a procedure that treats issues with your bile and pancreatic ducts by combining upper gastro endoscopy and X-rays. The damaged bile duct and the gallstones are located with the aid of ERCP by a medical practitioner. This test is more invasive than other tests, or it places more equipment within your body. Selectively, doctors utilize it, usually to remove a gallstone that has become lodged in the common bile duct.

CT scan

The term "computed tomography," (CT) scan, refers to a computerized X-ray imaging procedure in which a narrow beam of X-rays is aimed at a patient and quickly rotated around the body, producing signals that are processed by the machine's computer to generate cross-sectional images, or "slices." These slices are called tomographic images and can give a clinician more detailed information than conventional X-rays. Once several

successive slices are collected by the machine's computer, they can be digitally "stacked" together to form a three-dimensional (3D) image of the patient that allows for easier identification of basic structures as well as possible tumors or abnormalities. Through computer processing, cross-sectional images (slices) of the bones, blood arteries, and soft tissues inside your body are produced during a CT scan, which combines several X-ray images collected from various angles all over your body. Images from a CT scan offer more information than an X-ray would. This technique is painless, noninvasive, and precise (Grand et al., 2004).

There are various applications for a CT scan, but it is especially useful for immediately examining patients who may have internal damage from automobile accidents or other types of traumas. Nearly every region of the body may be seen using a CT scan, which is also used to plan medical, surgical, or radiation treatments as well as detect diseases and injuries. A CT scanner employs a motorized X-ray source that spins around the circular opening of a donut-shaped frame called a gantry, in contrast to a traditional X-ray, which uses a stationary X-ray tube. In a CT scan, the patient is lying on a bed that gently rotates across the gantry as a narrow beam of X-rays is shot into the body by the X-ray tube. Instead of film, CT scanners employ unique digital X-ray detectors, which are situated immediately opposite the X-ray source. As the X-rays leave the patient, they are picked up by the detectors and relayed to a computer. The CT computer constructs a two-dimensional imaging slice of the patient using advanced mathematical methods each time the X-ray source completes one full revolution. Depending on the CT equipment being used, the thickness of the tissue shown in each imaging slice might change, but it typically ranges from 1 to 10 mm. After finishing a full slice, the image is saved, and the motorized bed is slowly lowered onto the gantry. Then another image slice is created by repeating the X-ray scanning procedure. This procedure is repeated until the required number of slices has been gathered. The computer can either display the image slices individually or stack them together to create a 3D image of the patient that displays the skeleton, organs, tissues, and any anomalies the doctor is hoping to spot. This approach has various benefits, including the ability to rotate the 3D image in space or to see slices one after the other, which makes it simpler to pinpoint the precise location of a potential problem.

A CT scan can be used to diagnose acute gallbladder illness, gallstones, polyps, and occasionally gallbladder sludge (Andrén-Sandberg, 2012). The scan is typically performed when the patient is getting a preliminary

examination in the emergency room and the precise diagnosis is not evident. In situations of acute cholecystitis, pericholic fluid and a thicker gallbladder wall may be observed. A thicker gallbladder wall may be a nonspecific sign of chronic cholecystitis. An imaging test called a CT scan can also detect gallstones and gallbladder sludge.

When conducting a workup for possible gallbladder cancer, the CT scan is likely the test that will be the most helpful. This noninvasive test can assess the tumor's size, any metastases, and whether the liver has been directly or grossly affected by the tumor. A CT scan may be carried out to look for any complications of gallstones, such as acute pancreatitis. CT scans use a combination of X-rays and computer technology to create images of your gallbladder (de Savornin Lohman et al., 2019).

In this type of scan, a series of X-rays are taken from many different angles. CT scans are often carried out in an emergency to diagnose severe abdominal pain. the main advantage of a CT scan is that it can easily detect abnormal conditions in a patient's body. In a single scan, pictures are taken that measure the patient's body's structure and metabolic performance. It is a reasonably painless process. A CT scan can help you save time because the image-by-image scans only take a little over 30 minutes to complete. One of the biggest benefits of CT imaging is that it may image bone, soft tissue, and blood vessels all at once. Modern CT scanners expose people to additional health concerns and generate rather high levels of ionizing radiation. Additionally, contrast media may result in significant allergic reactions in people who have many CT scans (Fig. 11.3).

Nuclear medicine

In this nuclear medicine test, radioactive dye is injected intravenously and secreted into the bile. Cholecystitis is likely if the scan shows bile doesn't make it from the liver into the gallbladder. A hepatobiliary iminodiacetic acid, or HIDA, the scan is advised if acute cholecystitis is suspected and there is no evidence of gallbladder disease via ultrasonography. Technetium Tc 99 m injections intravenously are used for this. The liver absorbs it and excretes it through the biliary system. If the gallbladder does not fill up, the cystic duct is completely blocked, either mechanically or functionally. This result provides a nearly perfect diagnosis of acute cholecystitis. A patient may have chronic acalculous cholecystitis if they exhibit nonacute cholecystitis or biliary cholic symptoms, but the gallbladder ultrasound comes out negative. This is a functional issue brought on by the gallbladder's hypokinetic emptying.

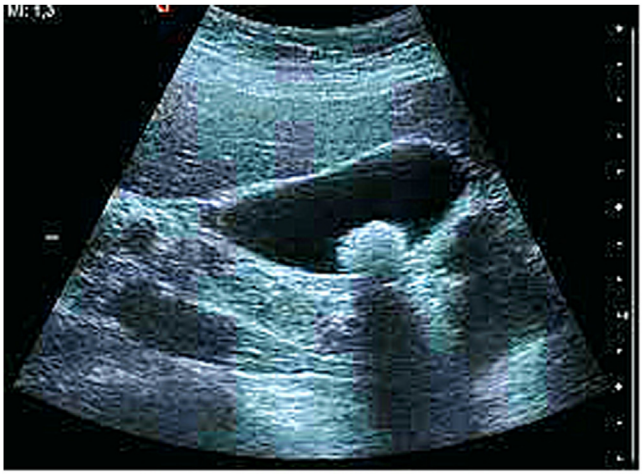

Figure 11.3 CT scan image of gallstone. *Adapted from open access.*

A HIDA scan with KINAVAC is the most effective diagnostic test for this illness (cholecystokinin-CCK). Tc 99 m is given as part of a standard HIDA scan. The KINAVAC is given intravenously once the gallbladder has been seen. The gallbladder contracts and empties because of this mimicking eating. The ejection fraction (EF), or percentage of the gallbladder emptying, is calculated digitally. Ejection fractions under 30%–35% are regarded as abnormal and may be a sign of acalculous cholecystitis. The documented recurrence of symptoms following KINAVAC injection may also be a sign of gallbladder disease. According to certain studies, a HIDA scan can accurately detect acalculous cholecystitis with a low EF 95% of the time. According to other studies, a HIDA scan's accuracy could be affected by the presence of other ailments, especially other gastrointestinal (GI) conditions (Gupta et al., 2018).

Conclusions

The procedure that is most frequently used to check for gallstone symptoms is abdominal ultrasonography. A transducer is moved back and forth across your stomach area during abdominal ultrasonography. The transducer transmits impulses to the computer, which generates images of the abdominal structures. A method called EUS can assist in finding tiny stones that an abdominal ultrasound might miss. A small, flexible tube called an endoscope is passed through your mouth and digestive tract by

your doctor during an EUS. A tiny ultrasound transducer inside the tube emits sound waves that precisely depict the tissue in the vicinity. Oral cholecystography, a HIDA scan, CT, MRCP, or ERCP are examples of additional procedures that may be performed. When gallstones are found via ERCP, they can be removed.

Acknowledgment

The authors gratefully acknowledge the support of the Amity University Jharkhand, Ranchi, Presidency University, Bangalore, M S Ramaiah Institute of Technology, Bangalore, Nitte Meenakshi Institute of Technology, Bangalore.

References

Andrén-Sandberg, A. (2012). Diagnosis and management of gallbladder polyps. *North American Journal of Medical Sciences*, *4*(5), 203–211. Available from https://doi.org/10.4103/1947-2714.95897.

de Savornin Lohman, E. A. J., de Bitter, T. J. J., van Laarhoven, C. J. H. M., Hermans, J. J., de Haas, R. J., & de Reuver, P. R. (2019). The diagnostic accuracy of CT and MRI for the detection of lymph node metastases in gallbladder cancer: A systematic review and meta-analysis. *European Journal of Radiology*, *110*, 156–162. Available from https://doi.org/10.1016/j.ejrad.2018.11.034.

Foster, F. S., Pavlin, C. J., Harasiewicz, K. A., Christopher, D. A., & Turnbull, D. H. (2000). Advances in ultrasound biomicroscopy. *Ultrasound in Medicine and Biology*, *26*(1), 1–27. Available from https://doi.org/10.1016/S0301-5629(99)00096-4.

Grand, D., Horton, K. M., & Fishman, E. (2004). CT of the gallbladder: Spectrum of disease. *American Journal of Roentgenology*, *183*(1), 163–170. Available from https://doi.org/10.2214/ajr.183.1.1830163.

Gupta, A., LeBedis, C. A., Uyeda, J., Qureshi, M. M., Anderson, S. W., & Soto, J. A. (2018). Diffusion-weighted imaging of the pericholecystic hepatic parenchyma for distinguishing acute and chronic cholecystitis. *Emergency Radiology*, *25*(1), 7–11. Available from https://doi.org/10.1007/s10140-017-1548-9.

Jones, M. W., Kashyap., & Ferguson. (2021). *Gallbladder imaging*. StatPearls Publishing.

Negrão De Figueiredo, G., Mueller-Peltzer, K., Zengel, P., Armbruster, M., Rübenthaler, J., & Clevert, D. A. (2019). Contrast-enhanced ultrasound (CEUS) and gallbladder diseases—A retrospective mono-center analysis of imaging findings with histopathological correlation. *Clinical Hemorheology and Microcirculation*, *71*(2), 151–158. Available from https://doi.org/10.3233/CH-189405.

Rumack, C. M., Wilson, S. R., & Charboneau, J. W. (1998). *Diagnostic ultrasound* (pp. 961–973). Mosby-Year Book. Inc.

Sanders, G., & Kingsnorth, A. N. (2007). Gallstones. *British Medical Journal*, *335*(7614), 295–299. Available from https://doi.org/10.1136/bmj.39267.452257.AD.

Smereczyński, A., Kołaczyk, K., & Bernatowicz, E. (2020). Optimization of diagnostic ultrasonography of the gallbladder based on own experience and literature. *Journal of Ultrasonography*, *20*(80), e29–e35. Available from https://doi.org/10.15557/jou.2020.0006.

Turnbull, D. H. (1999). In utero ultrasound backscatter microscopy of early stage mouse embryos. *Computerized Medical Imaging and Graphics*, *23*(1), 25–31. Available from https://doi.org/10.1016/S0895-6111(98)00060-3.